

## A Triathlete with Lateral Retromalleolar Pain

Édouard Giroux<sup>1</sup>, Martin Lamontagne<sup>2</sup>, Mathieu Boudier-Revéret<sup>2\*</sup>

<sup>1</sup>Department of Family Medicine, University of Montreal, Montreal, Canada, <sup>2</sup>Department of Physical Medicine and Rehabilitation, University of Montreal Health Center, Montreal, Montreal, Canada

### SECTION 2 – ANSWER

A 47-year-old triathlete with pain to his lateral left ankle was referred for a musculoskeletal ultrasound evaluation. He had no past medical history. Eighteen months prior to consultation, he had a sudden onset of sharp pain in the retro-malleolar area while climbing a hurdle during an obstacle race. No swelling was noted. Physiotherapy and foot orthosis did not help. He was not able to resume running. Twelve months after the injury, an magnetic resonance imaging (MRI) revealed mild tendinopathy and tenosynovitis of the fibular tendons and lateral malleolus bone marrow edema. A corticosteroid injection of the fibular sheath done under ultrasound guidance was performed and did not help him. Upon review of the MRI imaging, there was a suspicion of longitudinal split tear of the fibular brevis tendon and a retinaculum tear.

On physical exam, he had bilateral pes cavum. There was no swelling or atrophy in the ankle region. Gait and ankle range of motion were normal. Tiptoeing and jumping reproduced his left lateral ankle pain. He did not have pain on isometric testing of the fibular brevis tendon and mild discomfort on isometric testing of the fibular longus tendon. He had mild pain upon palpation of the retromalleolar area, as well as at the attachment of the fibular retinaculum on the posterolateral malleolus. There was a doubt regarding possible subluxation of the fibular tendons with resisted active eversion.

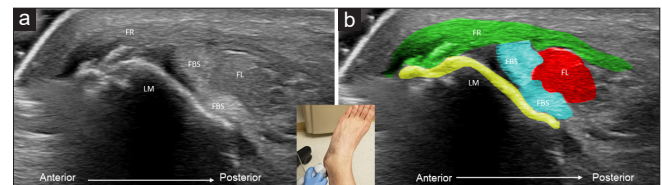
Static ultrasound (*Philips Epiq 5*, 7-18 mHz multi-frequency linear probe) of the lateral ankle revealed a tear of the superior part of the fibular retinaculum at its malleolar insertion with associated cortical irregularities, a longitudinal fibularis brevis split tear [Figure 1] and dynamic ultrasound an anterior subluxation [Figure 2] of only its anterior portion over the lateral malleolus [Supplementary Video 1]. The

patient was referred to an orthopedic surgeon for surgical management.

Instability of the fibular tendons is a well-known pathology of the lateral ankle. It can be separated between anterior instability and intrasheath instability. Anterior instability is an abnormal anterior displacement of one of the tendons over the fibula. It is mostly caused by a posttraumatic tear of the superior fibular retinaculum.<sup>[1,2]</sup>

Intrasheath instability consists of subluxation of the tendons between each other and may cause a split tear of one of them.<sup>[1,3]</sup> It usually causes a painful “popping” or “clicking” sensation, but may be present on MRI imaging in up to 15% of asymptomatic individuals.<sup>[4]</sup> The prevalence of fibularis brevis tear is between 11% and 37% in cadaveric studies.<sup>[5]</sup>

Acute fibular dislocations are misdiagnosed in up to 40% of cases.<sup>[5]</sup> A split tear of the fibular brevis tendon can be treated conservatively.<sup>[6]</sup> When a chronic instability is present, surgical management is recommended.<sup>[1,7]</sup>



**Figure 1:** Ultrasound view of the lateral ankle at rest without (a) and with (b) added colors. The fibularis brevis split (in blue) tendons are both in the fibular groove of the lateral malleolus (in yellow), with the fibularis longus (in red) sitting between them. The superior fibular retinaculum (in green) is thickened with a tear at its fibular insertion

Received: 28-03-2021 Revised: 20-04-2021 Accepted: 28-04-2021 Available Online: 29-07-2021

Video Available on: [www.jmuonline.org](http://www.jmuonline.org)

#### Access this article online

##### Quick Response Code:



Website:  
[www.jmuonline.org](http://www.jmuonline.org)

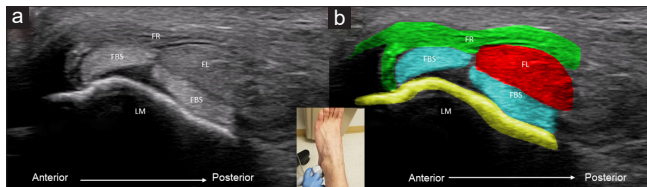
DOI:  
10.4103/JMU.JMU\_68\_21

**Address for correspondence:** Dr. Mathieu Boudier-Revéret,  
Department of Physical Medicine and Rehabilitation, University of Montreal  
Health Center, Montreal, Canada, 3840 St Urbain St, Montreal, QC, H2W  
1T8, Canada.  
E-mail: [mathieu.boudier-reveret@umontreal.ca](mailto:mathieu.boudier-reveret@umontreal.ca)

This is an open access journal, and articles are distributed under the terms of the Creative Commons Attribution-NonCommercial-ShareAlike 4.0 License, which allows others to remix, tweak, and build upon the work non-commercially, as long as appropriate credit is given and the new creations are licensed under the identical terms.

**For reprints contact:** [WKHLRPMedknow\\_reprints@wolterskluwer.com](mailto:WKHLRPMedknow_reprints@wolterskluwer.com)

**How to cite this article:** Giroux É, Lamontagne M, Boudier-Revéret M. A triathlete with lateral retromalleolar pain. *J Med Ultrasound* 2022;30:310-1.



**Figure 2:** Ultrasound view of the actively everted lateral ankle without (a) and with (b) added colors. The most anterior part of the split fibularis brevis split tendon subluxates anteriorly over the lateral malleolus while the other stays in the fibular groove

This case presents a rare combination of both types of instability in the same ankle; anterior fibular instability combined with intrasheath instability. Instability of the fibular tendons is a dynamic phenomenon and static imaging may be falsely negative. As we demonstrated in this case, dynamic ultrasonography is the imaging modality of choice to evaluate fibular tendon instability in patients with lateral ankle pain.

#### Declaration of patient consent

The authors certify that they have obtained all appropriate patient consent forms. In the patient has given his consent for his images and other clinical information to be reported in the journal. The patient understands that his name and initials will not be published and due efforts will be made to conceal the identity, but anonymity cannot be guaranteed.

#### Financial support and sponsorship

Nil.

#### Conflicts of interest

There are no conflicts of interest.

#### REFERENCES

1. Pesquer L, Guillo S, Poussange N, Pele E, Meyer P, Dallaudière B. Dynamic ultrasound of peroneal tendon instability. *Br J Radiol* 2016;89:20150958.
2. Wu CH, Shyu SG, Özçakar L, Wang TG. Dynamic ultrasound imaging for peroneal tendon subluxation. *Am J Phys Med Rehabil* 2015;94:e57-8.
3. Hsiao MY, Shyu SG, Wu CH, Özçakar L. Dynamic ultrasound imaging for type A intrasheath subluxation of the peroneal tendons. *Am J Phys Med Rehabil* 2015;94:e53-4.
4. O'Neil JT, Pedowitz DI, Kerbel YE, Coddling JL, Zoga AC, Raikin SM. Peroneal tendon abnormalities on routine magnetic resonance imaging of the foot and ankle. *Foot Ankle Int* 2016;37:743-7.
5. Davda K, Malhotra K, O'Donnell P, Singh D, Cullen N. Peroneal tendon disorders. *EFORT Open Rev* 2017;2:281-92.
6. Wang XT, Rosenberg ZS, Mechlin MB, Schweitzer ME. Normal variants and diseases of the peroneal tendons and superior peroneal retinaculum: MR imaging features. *Radiographics* 2005;25:587-602.
7. Ferran NA, Oliva F, Maffulli N. Recurrent subluxation of the peroneal tendons. *Sports Med* 2006;36:839-46.